A63-272 Kennedy, John F.

Date of birth __ __ 1917

Date of death 11/22/63

Hour of death 1$^{00}_{PM}$ CST Dallas, Tex.

Hour of autopsy 8$^{00}_{PM}$ EST Bethesda, Md.

Clinical Summary

According to available information the deceased, President John F. Kennedy, was riding in an open car in a motorcade during an official visit to Dallas, Texas on 22 Nov. 1963. The president was sitting in the right rear seat with Mrs. Kennedy seated on the same seat to his left. Sitting directly in front of the president was Gov. John B. Connally of Texas and directly in front of Mrs. Kennedy sat Mrs. Connally. The vehicle was moving at a slow rate of speed ~~approximately twenty miles per hour~~ down an incline into an underpass that leads to a freeway route to the Dallas Trade Mart where the president was to deliver ~~give~~ an address.

GBB Three shots were heard and the president fell forward ~~face downward to the floor of the vehicle~~

bleeding from the head. (Governor Connally was seriously wounded by the same gunfire). According to newspaper reports (Washington Post Nov. 23, 1963) Bob Jackson, a Dallas Times Herald photographer, said he looked around as he heard the shots and saw a rifle barrel disappearing into a window on an upper floor of the nearby Texas School Book Depository building.

Shortly following the wounding of the two men the car was driven to Parkland Hospital. In the emergency room of that hospital the president was attended by Dr. Malcolm Perry. Telephone communication with Dr. Perry on Nov. 23, 1963 develops the following information relative to the observations made by Dr. Perry and procedures performed there prior to death.

Dr. Perry noted the massive wound of the head and a second, puncture wound, of the low anterior neck in approximately the midline. A tracheostomy was performed by extending the latter wound. At this point bloody air was noted bubbling from the wound and an injury to the R. lateral wall of the trachea was observed. Incisions were made in the upper anterior chest wall bilaterally to combat possible sub-cutaneous emphysema. Intravenous infusions of blood and saline were begun and oxygen was administered. Despite these measures cardiac arrest occurred and closed chest cardiac massage failed to re-establish cardiac action. The president was pronounced dead approximately thirty to forty minutes after receiving his wounds.

The remains were transported via the presidential plane to Washington D.C. and subsequently to the Naval Medical School, National Naval Medical Center, Bethesda, Md. for post-mortem examination.

General Description of Body The body is that of a muscular, well developed and well nourished adult caucasian male measuring 72 1/2 inches and weighing approximately

170 lbs. There is beginning rigor mortis, minimal dependent livor mortis of the dorsum and early algor mortis. The hair is reddish-brown and abundant, the eyes are blue the rt. pupil measuring 8 mm. in diameter, the left 4 mm. There is edema and ecchymosis of the inner canthus region of the left eye lid measuring approximately 1.5 cm in greatest diameter. There is edema and ecchymosis diffusely over the rt. supra-orbital ridge with abnormal mobility of the underlying bone. (The remainder of the scalp will be described with the skull.) There is clotted blood on the external ears but otherwise the ears, nares and mouth are essentially unremarkable. The teeth are in excellent repair and there is some pallor of the oral mucous membrane.

Situated on the upper rt. posterior thorax just above the upper border of the scapula there is a 7 x 4 mm oval ~~[illegible]~~ wound. This wound is measured to be 14 cm. from the tip of the rt. acromion process and 14 cm. below the tip of the rt. mastoid process.

Situated in the low anterior neck at approximately the level of the third and fourth tracheal rings is a 6.5 cm. long transverse wound with widely gaping irregular edges. (The depth and character of these wounds will be further described below.)

Situated on the anterior chest wall in the nipple line are bilateral 2 cm. long recent transverse surgical incisions into the subcutaneous tissue. The one on the left is situated 11 cm. cephalad to the nipple and the one on the right 8 cm. cephalad to the nipple. There is no hemorrhage or ecchymosis associated with these wounds. A similar clean wound measuring 2 cm. in length is situated on the antero-lateral aspect of the ~~right~~ left mid arm. Situated on the antero-lateral aspect of each ankle is a recent 2 cm. transverse incision into the sub-cutaneous tissue.

There is an old well healed 8 cm. McBurney abdominal incision. Over the lumbar spine in the midline is an old, well healed 15 cm. scar. Situated on the upper antero-lateral aspect of the rt. thigh is an old, well healed 8 cm scar.

Missile Wounds

1. There is a large irregular defect of the scalp and skull on the right involving chiefly the parietal bone but extending somewhat into the temporal and occipital regions. In this region there is an actual absence of scalp and bone producing a defect which measures approximately 13 cm. in greatest diameter.

From the irregular margins of the above scalp defect tears extend in stellate fashion into more or less intact scalp as follows:

(a) From the right inferior temporoparietal margin anterior to the rt. ear to a point slightly above the tragus.

b) From the anterior parietal margin anteriorly on the forehead to approximately 4 cm. above the rt. orbital ridge

c) From the left margin of the main defect across the midline antero-laterally for a distance of approximately 8 cm.

d) From the same starting point as (c) 10 cm postero-laterally.

Situated in the posterior scalp approximately 2.5 cm laterally to the right and slightly above the external occipital protuberance is a ~~[illegible]~~ lacerated wound ~~tangential to the surface of the scalp~~ measuring 15 X 6 mm. In the underlying bone is a corresponding ~~[illegible]~~ wound through ~~both tables of~~ the bone of the skull which exhibits ~~chipping~~ beveling of the margins ~~of the inner table~~ of the bone when viewed from the inner ~~[illegible]~~ aspect of the skull.

Clearly visible in the above described large skull defect and exuding from it is ~~[illegible]~~ lacerated brain tissue which on close inspection proves to represent ~~the~~

the major portion of the right cerebral hemisphere. At this point it is noted that the falx cerebri is extensively lacerated with disruption of the superior saggital sinus.

Upon reflecting the scalp multiple complete fracture lines are seen to radiate from both the large defect at the vertex and the smaller [illegible] wound at the occiput. These vary greatly in length and direction the longest measuring approximately 19 cm. These result in the production of numerous fragments which vary in size from a few millimeters to 10 cm. in greatest diameter.

The complexity of these fractures and the fragments thus produced tax satisfactory verbal description and are better appreciated in photographs and ~~x-ray~~ roentgenograms which are prepared.

The brain is removed and preserved for further study following formalin fixation.

Received as separate specimens from Dallas, Tex. are three fragments of skull bone which in aggregate roughly approximate the dimensions of the large defect described above. At one angle of the largest of these fragments is a portion of the perimeter of a roughly circular wound of presumably exit which exhibits ~~[illegible]~~ beveling of the outer ~~table~~ aspect of the bone and is estimated to measure approximately 2.5 to 3.0 cm in diameter. Roentgenograms of this fragment reveal minute ~~fragments~~ particles of metal in the bone at this margin. Roentgenograms of the skull reveal multiple minute metallic fragments along a line corresponding with a line joining the above described ~~occipital~~ small occipital ~~puncture~~ wound and the R. supra-orbital ridge. From the surface of the disrupted R. cerebral cortex two small irregularly shaped fragments of metal are recovered. These measure 7 x 2 mm + 3 x 1 mm. These are placed in the custody of agents Francis X. O'Neill Jr. and James W. Sibert of the Federal Bureau of Investigation, ~~I~~, who executed a receipt therefor (attached)

2. The second wound presumably of entry is that

described above in the upper rt. posterior thorax. Beneath the skin there is ecchymosis of sub-cutaneous tissue and musculature. The missile path through the fascia and musculature cannot be easily probed. The wound presumably of exit was that described by Dr. Malcolm Perry of Dallas in the low anterior cervical region. When observed by Dr. Perry the wound measured a "few millimeters in diameter" however it was extended as a tracheotomy incision and thus its character is distorted at the time of autopsy. However there is considerable ecchymosis of the strap muscles of the rt side of the neck and of the fascia about the trachea adjacent to the line of the tracheotomy wound. The third point of reference in connecting these two wounds is in the apex (supra-clavicular portion) of the rt. pleural cavity. In this region there is contusion of the parietal pleura and of the extreme apical portion of the rt. upper lobe of the lung. In both instances the diameter of contusion and ecchymosis at the point of maximal involvement measures 5 cm. Both the visceral and parietal pleura is intact overlying these areas of trauma.

Incisions: The scalp wounds are extended in the coronal plane to examine the cranial contents and the customary "Y" shaped incision is used to examine the body cavities.

Thoracic Cavity - The bony cage is unremarkable. The thoracic organs are in their normal positions and relationships and there is no increase in free pleural fluid. The above described area of contusion in the apical portion of the rt. pleural cavity is noted.

Lungs - The lungs are of essentially similar appearance the rt. weighing 320 Gm, the left 290 Gm. The lungs are well aerated with smooth glistening pleural surfaces and gray-pink color. A 5 cm dia. area of purplish red discoloration and increased firmness to palpation is situated in the apical portion of the rt. upper lobe. This corresponds to the similar area described in the overlying parietal pleura. Incision in this region reveals recent hemorrhage into pulmonary parenchyma.

Heart - The ~~pleural~~ pericardial cavity is smooth walled and contains approximately 10 cc of straw-colored fluid. The heart is of essentially normal external contour and weighs 350 Gm. The pulmonary artery is opened in situ and no abnormalities are noted. The cardiac chambers contain moderate amounts of post-mortem clotted blood. There are no gross abnormalities of the leaflets of the cardiac valves. The following are the circumferences of the cardiac valves: aortic 7.5 cm, pulmonic 7 cm, tricuspid 12 cm, mitral 11 cm. The myocardium is firm and reddish-brown. The left ventricular myocardium averages 1.2 cm in thickness, the rt. ventricular myocardium 0.4 cm. The coronary arteries are dissected, are of normal distribution and smooth walled and elastic throughout.

Abdominal Cavity - The abdominal organs are in their normal positions and relationships and there is no increase in free peritoneal fluid. The vermiform appendix is surgically absent and there are a few adhesions joining the region of the cecum to the ventral abdominal wall at the above described old abdominal incisional scar.

Skeletal System - Aside from the above described skull wounds there are no significant gross skeletal abnormalities.

Photography - Black and white and color photographs ~~are prepared~~ depicting of significant ~~features~~ findings, Exposed but undeveloped

Roentgenograms - Roentgenograms are ~~prepared~~ made of the entire body and of the separately submitted three fragments of skull bone. Developed roentgenogram—

Summary Based on the above observations it is our opinion that the deceased died as a result of two perforating gunshot wounds inflicted by high velocity projectiles fired by a person or persons unknown. The projectiles were fired from a point behind and somewhat ~~[illegible]~~ above ~~a horizontal~~ ~~perpendicular~~ the level of the ~~president~~ ~~line to the vertical position of the body at the moments of impact~~. The observations and available information ~~do~~ not permit a satisfactory estimate as to the sequence of the two wounds.

The fatal missile entered the skull above and to the right of the external occipital protuberance. A ~~small~~ portion of the projectile traversed the cranial cavity in a posterior-anterior direction (see lateral skull roentgenograms) depositing minute particles along its path. ~~The major~~ A portion of the projectile made its exit ~~through~~ the parietal ~~[illegible]~~ bone on the right. ~~The two wounds~~ carrying with it portions of cerebrum, skull and scalp. The two wounds of the skull combined with the force of the missile produced extensive fragmentation of the skull, laceration of the superior saggital sinus and of the rt. cerebral hemisphere.

The ~~secondary~~ other missile entered the rt. superior posterior thorax above the scapula ~~to the right of the midline~~ and traversed the soft tissues of the supra-scapular and supra-clavicular portions of the base of the right side of the neck. This missile produced contusions of the rt. apical parietal pleura and of the apical portion of the rt. upper lobe of the lung. The missile contused the strap muscles of the rt. side of the neck, damaged the trachea and made its exit through the anterior surface of the neck. As far as can be ascertained this missile struck no boney structures in its path through the body.

A supplementary report will be submitted following more detailed examination of the brain and of microscopic sections. However, it is not ~~x~~ anticipated that these examinations will materially alter the findings.

JJH In addition it is our opinion that the wound of the skull produced such extensive damage to the brain as to preclude the possibility of the deceased surviving this injury

AUTOPSY

NMS # A 63 #272 DATE 11-22-63 HR. STARTED ______ HR.COMPLETED ______

NAME: ______ RANK/RATE ______

DATE/HOUR EXPIRED: ______ WARD ______ DIAGNOSIS ______

PHYSICAL DESCRIPTION: RACE: ______ Obtain following on babies only:

Height ____ in. Weight ____ lb. Color Hair ______ Crown-rump ______ in.
Crown-heel ______ in.

Color eyes ____ Pupils: Rt ____ mm, Lt. ____ mm Circumference:
Head ____ in. Chest ____ in.
Abd. ____ in.

WEIGHTS: (Grams, unless otherwise specified)

LUNG, RT.	~~[illegible]~~ 320	KIDNEY, RT.	1305	ADRENALS, RT.	
LUNG, LT.	~~[illegible]~~ 290	KIDNEY, LT.	140	ADRENALS, LT.	
BRAIN		LIVER	650	PANCREAS	
SPLEEN	90	HEART	350	THYROID	
THYMUS		TESTIS		OVARY	

HEART MEASUREMENTS: A 7.5 cm. P 7 cm. T 12 cm. M 10 cm.

LVM 1.5 cm. RVM .4 cm.

NOTES:

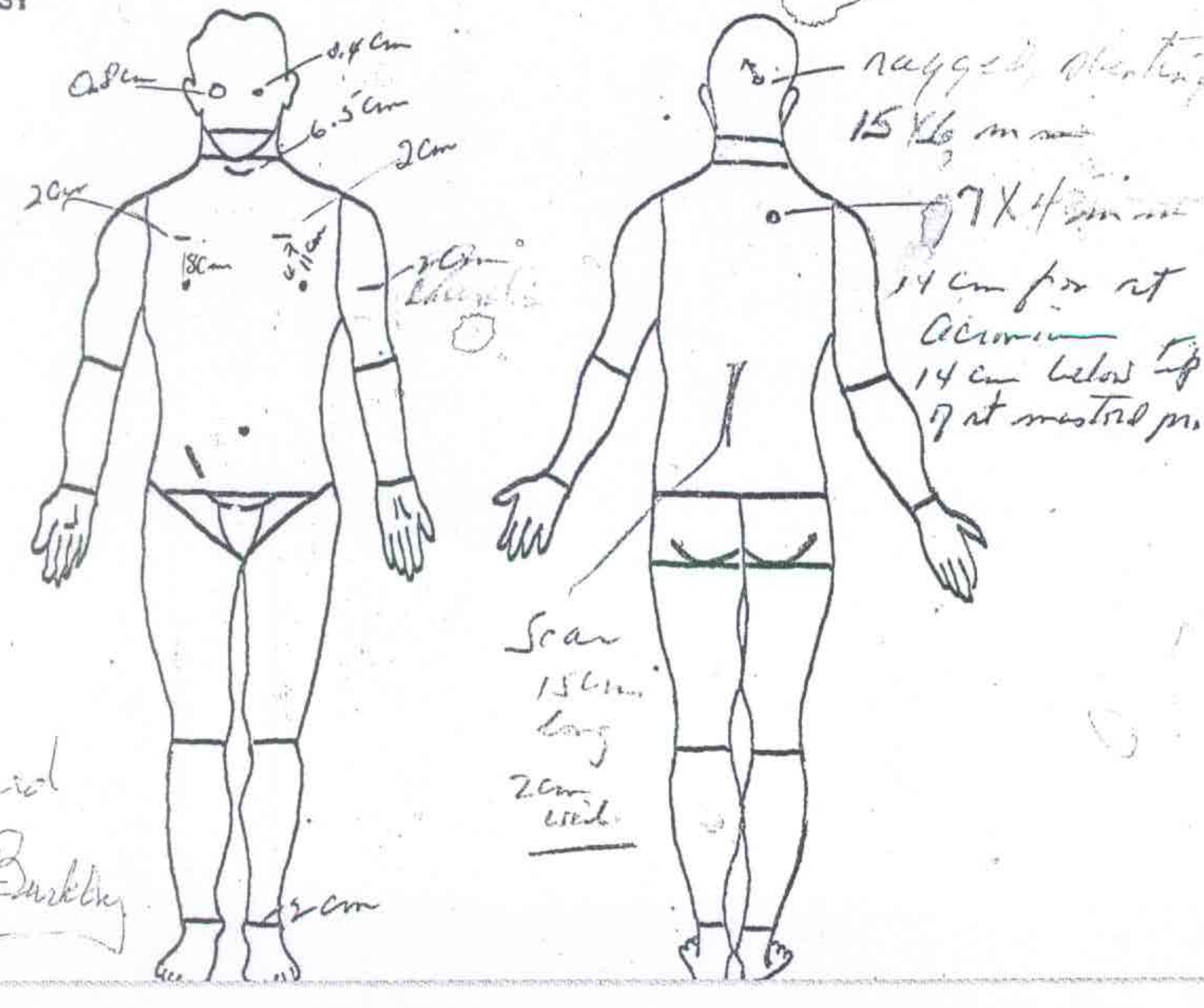
0.8 cm
0.4 cm
6.5 cm
2 cm
2 cm
18 cm
4.7
11 cm
7 cm
ragged slanting
15 x 6 mm
7 x 4 mm
14 cm fr rt
acromion
14 cm below tip
of rt mastoid process
Scar
15 cm
long
2 cm
wide
2 cm

Verified
GG Burkley

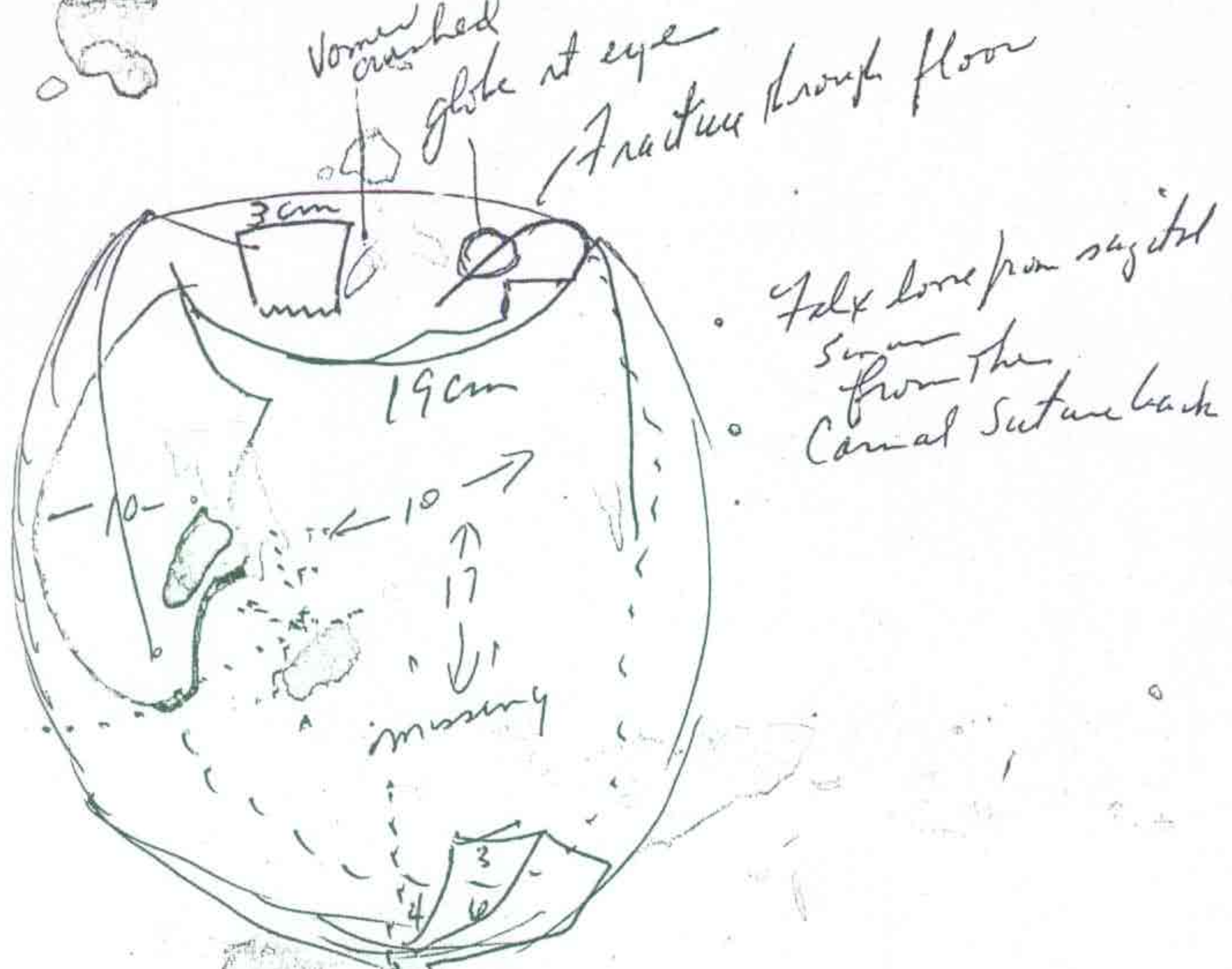
Vomer crushed
globe rt eye
Fracture through floor
3cm
19cm
10
10
17
missing
4
3
10

Falx loose from sagittal sinus from the Coronal Suture back